Female reproductive system

Prof.Dr./ Doaa Zaghloul

- The female reproductive system consists of two ovaries, two uterine tubes (oviducts), uterus, vagina and external genitalia.

- It is concerned with the production and transport of the **ova**, the transport of **spermatozoa**, fertilization and the accommodation of the conceptus until birth.

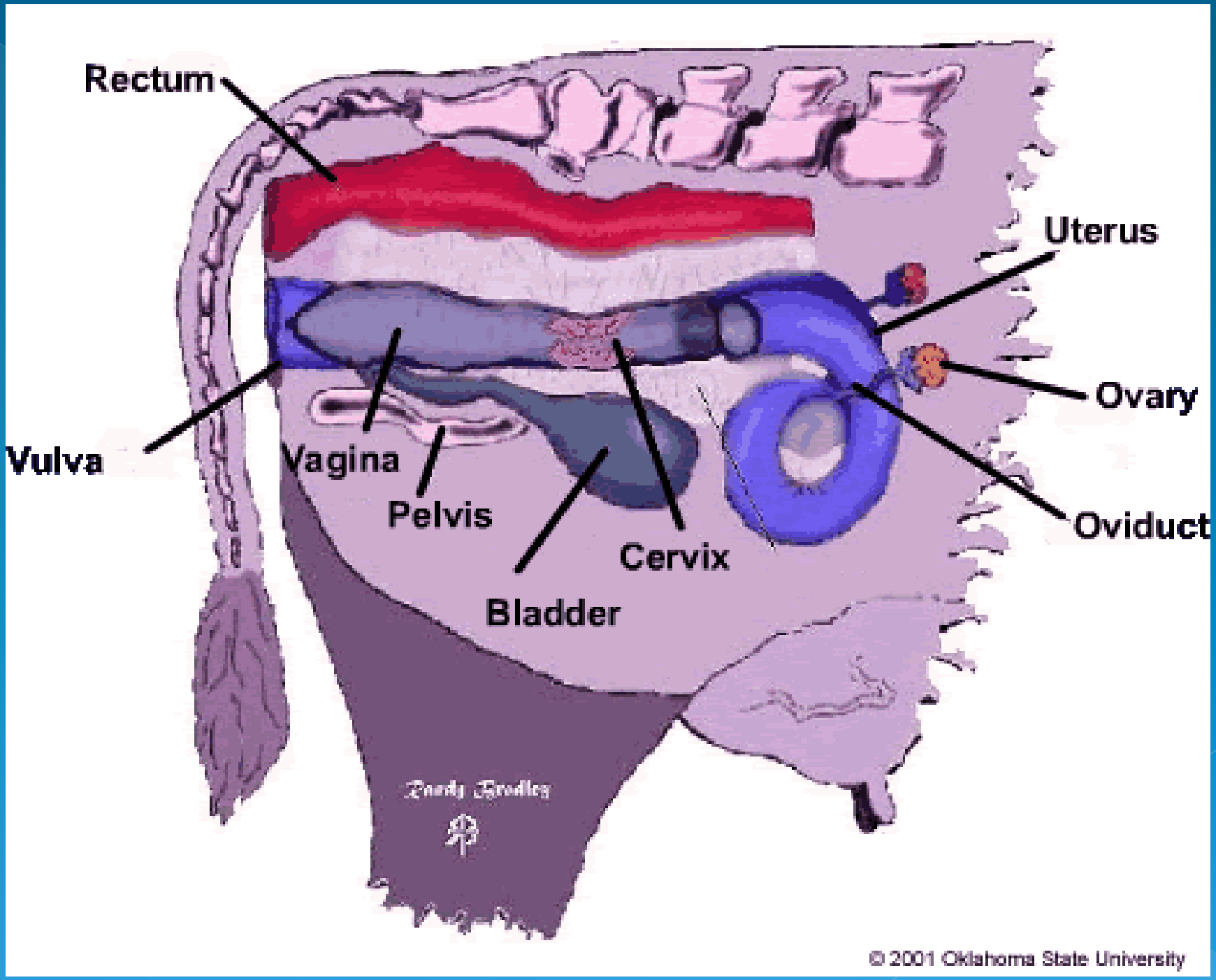
Rectum
Uterus
Ovary
Vulva
Vagina
Pelvis
Cervix
Oviduct
Bladder
© 2001 Oklahoma State University

Bovine Reproductive Tract

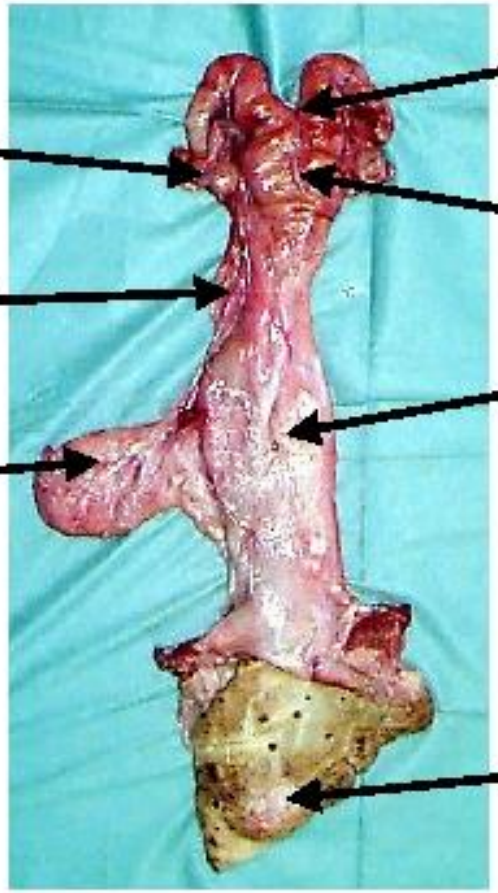

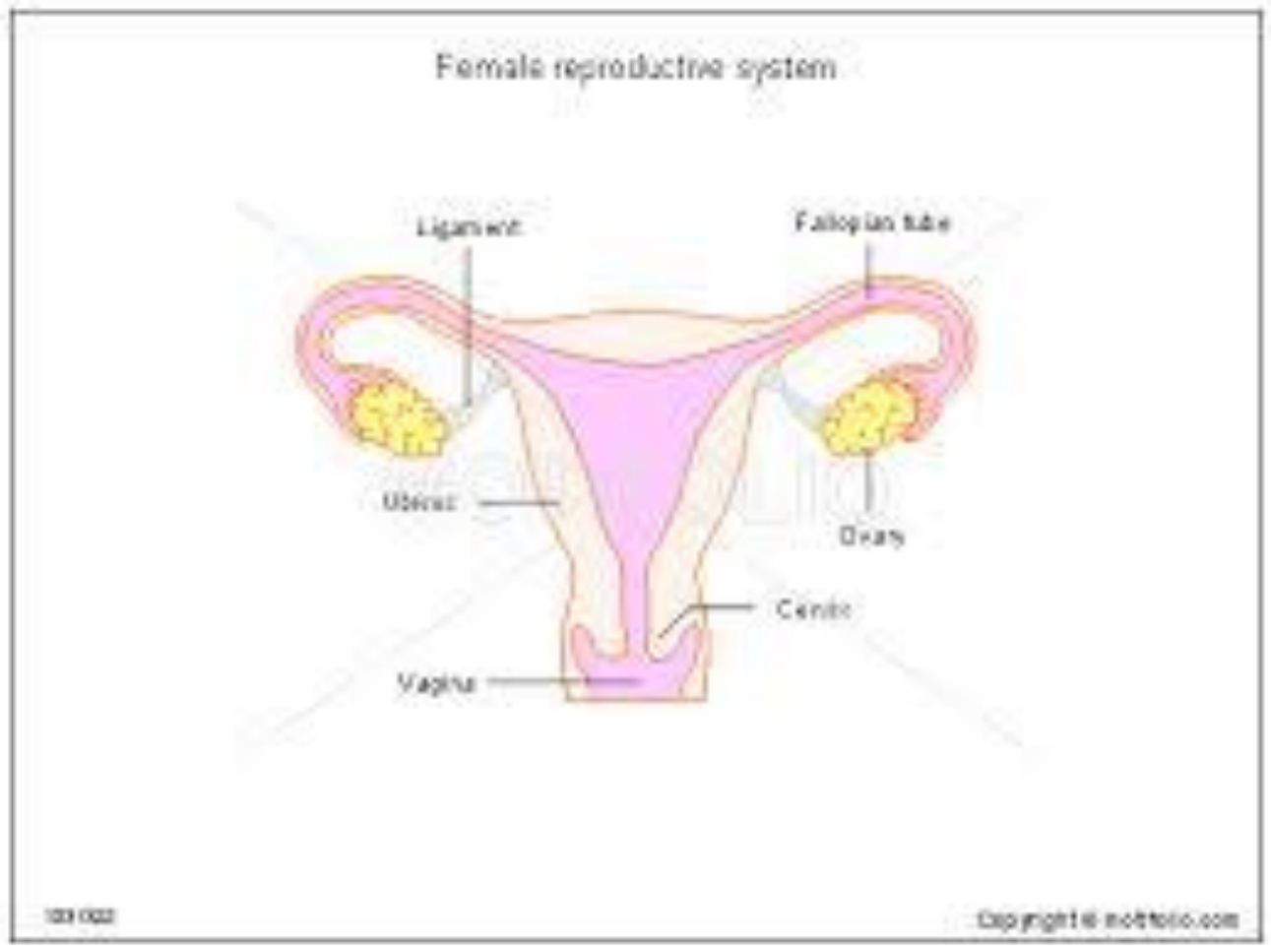
Female reproductive system
Ligament
Fallopian tube
Uterus
Ovary
Cervix
Vagina

Ovary

- The ovary is exocrine and endocrine gland. It produces the ova (exocrine secretion) and the ovarian hormones, the estrogen and the progesterone (endocrine secretion).

- It is an ovoid structure divided into an outer cortex and an inner medulla. In mature mare, these areas become reversed and the cortex reach the surface only through the ovulation fossa which is the site of all ovulation.

- **Cortex**

- The cortex is a broad peripheral zone containing ovarian follicles in various stages of development and corpora lutea embedded in a loose connective tissue stroma.

- It is covered by a low cuboidal surface epithelium, beneath it a thick connective tissue layer, the tunica albuginea.

- In rodents, bitch and queen, the cortical stroma contains cords of polyhedral interstitial endocrine cells.

- In bitch there are narrow channels lined by a cuboidal epithelium, cortical tubules that in some sites are continuous with the surface epithelium.

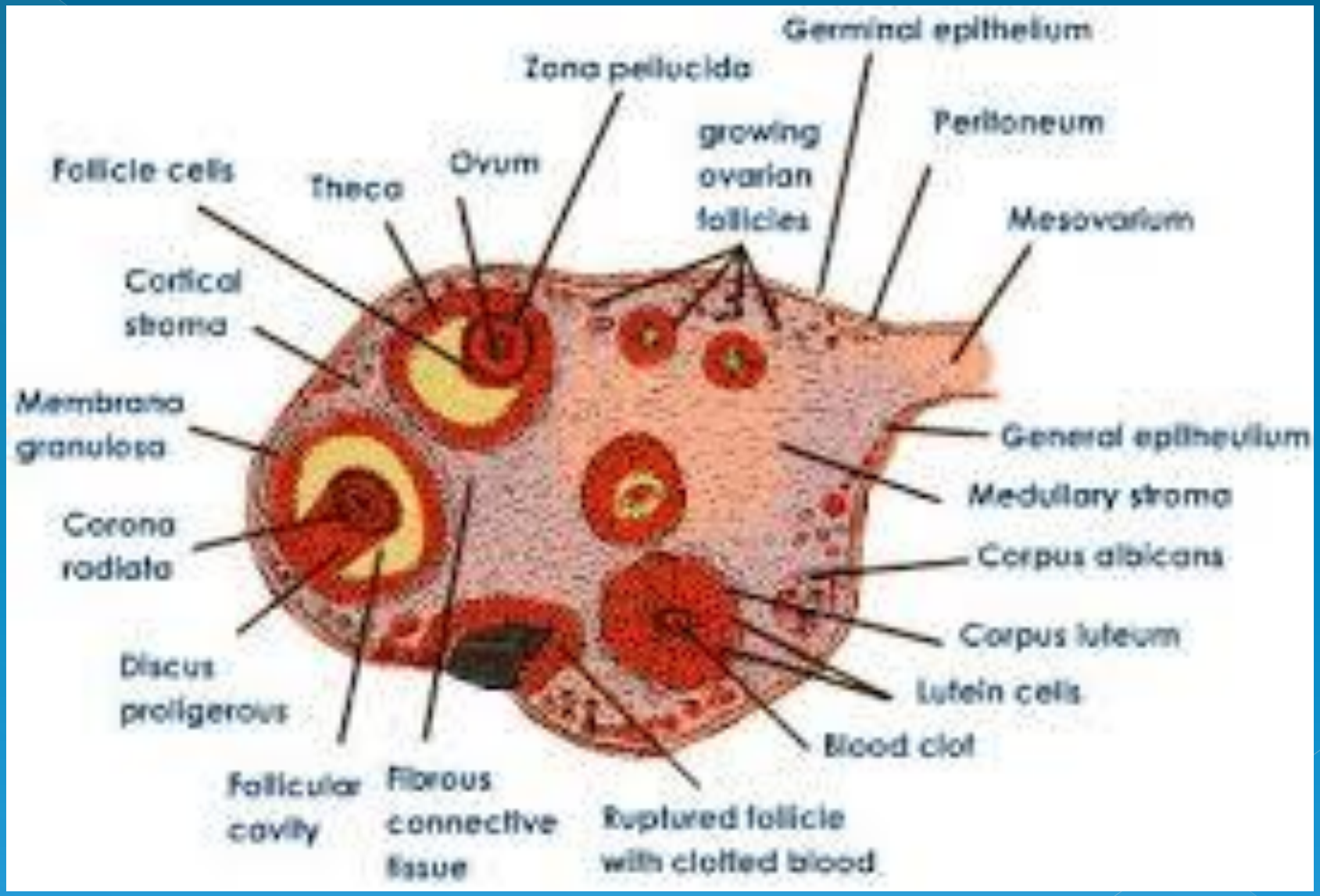
Germinal epithelium
Zona pellucida
Peritoneum
growing ovarian follicles
Follicle cells
Theca
Ovum
Mesovarium
Cortical stroma
Membrana granulosa
General epithelium
Medullary stroma
Corona radiata
Corpus albicans
Corpus luteum
Lutein cells
Discus proligerous
Blood clot
Follicular cavity
Fibrous connective tissue
Ruptured follicle with clotted blood

Ovarian Follicles

- Each follicle consists of a single oocyte surrounded by one or more layers of follicle cells.

1- Primordial follicle

- It is the earliest stage of follicle which arise prenatally and in bitch it arise also postnatally.

- Several hundred thousand to 1,000,000 follicles may be present at birth in one ovary. Most of these regress and only several hundred ovulate.

- Each consists of a primary oocyte surrounded by one layer of flat follicular cells resting on a basal lamina.

- These follicles are located mainly in the outer cortex, evenly distributed in ruminant and the sow and occur in clusters in carnivores.

2- Primary follicles (unilaminar)

- At puberty and under stimulation by pituitary FSH, some primordial follicles start to grow.

- This growth includes the oocyte, the follicular cells and the stromal connective tissue surrounding the follicles.

- The primary follicle is composed of a primary oocyte surrounded by a single layer of cuboidal follicular cells.

- The primary oocytes begin the first meiosis before birth, but the completion of prophase does not occur until the time of ovulation.

3- Secondary follicles (multilaminar)

- They are composed of a primary oocyte surrounded by more than one layer of polyhedral follicular cells termed granulosa cells.

- A thick glycoprotein layer the zona pellucida develop around the plasma membrane of the oocyte. It is secreted by the granulosa cells and in part by the oocyte.

- The zona pellucida is penetrated by microvilli from the oocyte and cytoplasmic extensions of the granulosa cells.

- Late in this stage of development, small fluid-filled cavities are formed among the granulosa cells.

- A vascularized multilaminar layer of spindle-shaped stroma cells termed **theca cells** begins to form around the granulosa cell layer in late secondary follicles

4- Tertiary follicles (antral)

- They are composed of a primary oocyte surround by many layers of granulosa cells. The cavities between these cells coalesced and formed a single large cavity containing liquor folliculi (antrum).

- The granulosa cells are surrounded by theca folliculi.

- It has a spherical centrally located nucleus with prominent nucleolus

- As the antrum enlarges, the granulosa cells are separated into an **outer regular layer** lined the follicular wall, termed stratum granulosum and a mass of cells connected with the stratum granulosum and containing the oocyte, called the **cumulus oophorus**.

- The epithelial follicular cells of the stratum granulosum lie on a **thick basal lamina**, which surrounded by the **theca folliculi** that diffrentiates into two layers: an inner vascular theca **interna** and an outer fibrous theca **externa**.

- Just before ovulation the tertiary follicle become mature follicle.

5- Mature Graafian follicle

- In mature follicles, before or just after ovulation depending on the species, the primary oocyte completes the first meiosis giving rise to a secondary oocyte and the first polar body.

- The mature follicle is so large that it occupies the whole thickness of the cortex and **bulges** on the surface of the ovary.

- It is a spherical thin walled vesicle with a large lumen, the antrum.

- In the theca interna, the spindle-shaped cells of the early tertiary follicles increased in size and become polyhedral and epithelioid.

- The epithelioid cells are typical steroid secreting cells.

- They secret androgen which convert by the granulosa cells into estrogen.

- The theca externa consists of a thin layer of loose connective tissue with fibroblasts and blood vessels, which supply the theca interna by capillaries.

- The basal lamina separates between the stratum granulosum and the theca interna.

- The secondary oocyte has lightly stained eccentrically situated nucleus and a granular yolk-containing cytoplasm.

- It is surrounded with thick striated layer the **zona pellucida**.

- The striation is due to the presence of **pores**.

- Around the zona pellucida the granulosa cells become columnar and radialy arranged forming the corona radiata for nutrient support for the oocyte.

- Cytoplasmic processes extend from these cells through the pores in the zona pellucida to the oocyte, as also microvilli from the oocyte .

- The corona radiata are lost at the time of ovulation in ruminant but they persist until before fertilization in other species.

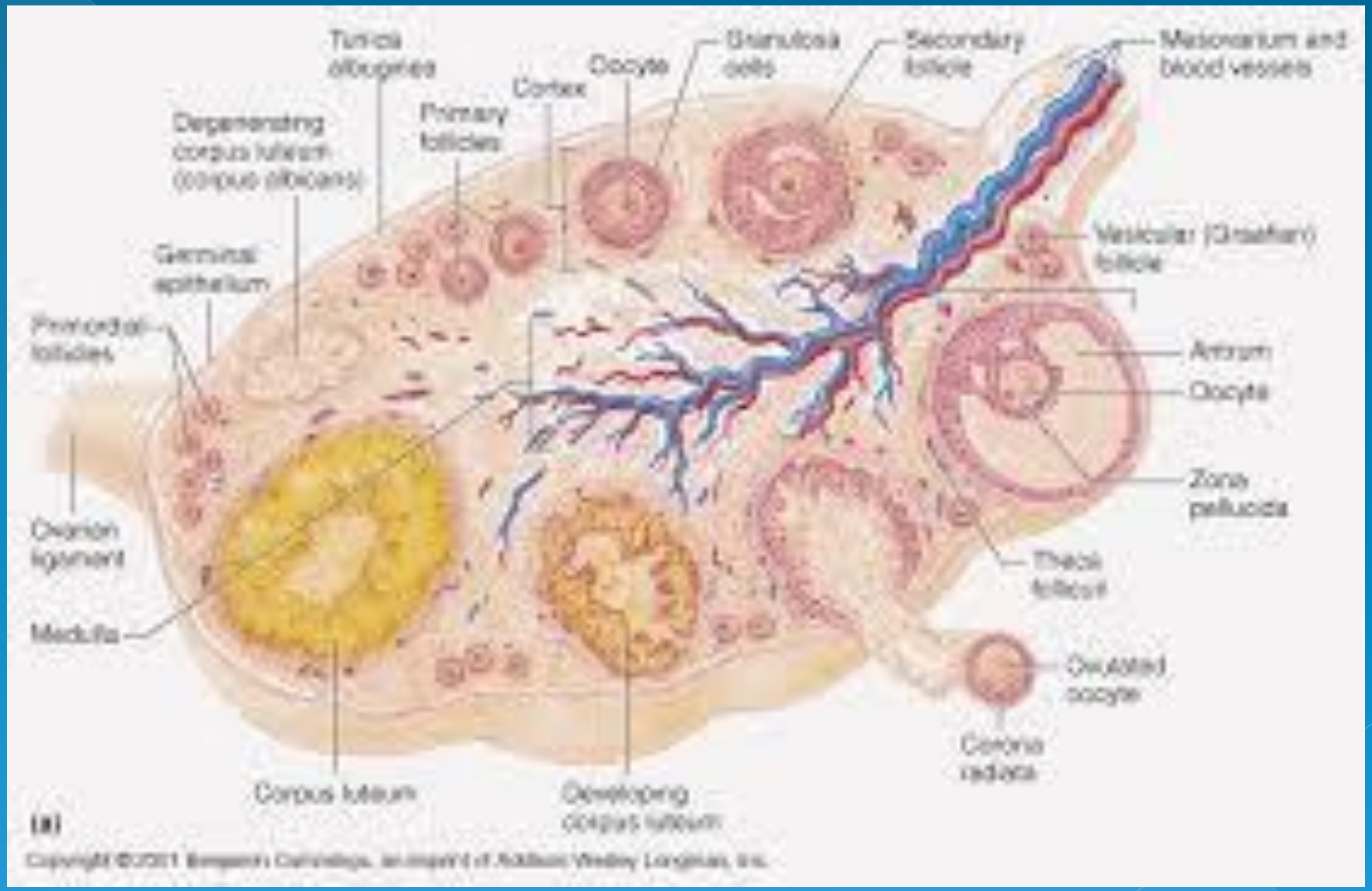

Copyright ©2001 Benjamin Cummings, an imprint of Addison Wesley Longman, Inc.

- In domestic animals, the first meiosis is completed shortly **before** ovulation <u>except in bitch and mare</u> in which it is completed shortly **after** ovulation.

- <u>At fertilization</u> the secondary oocyte becomes an ovum and the second polar body is given off.

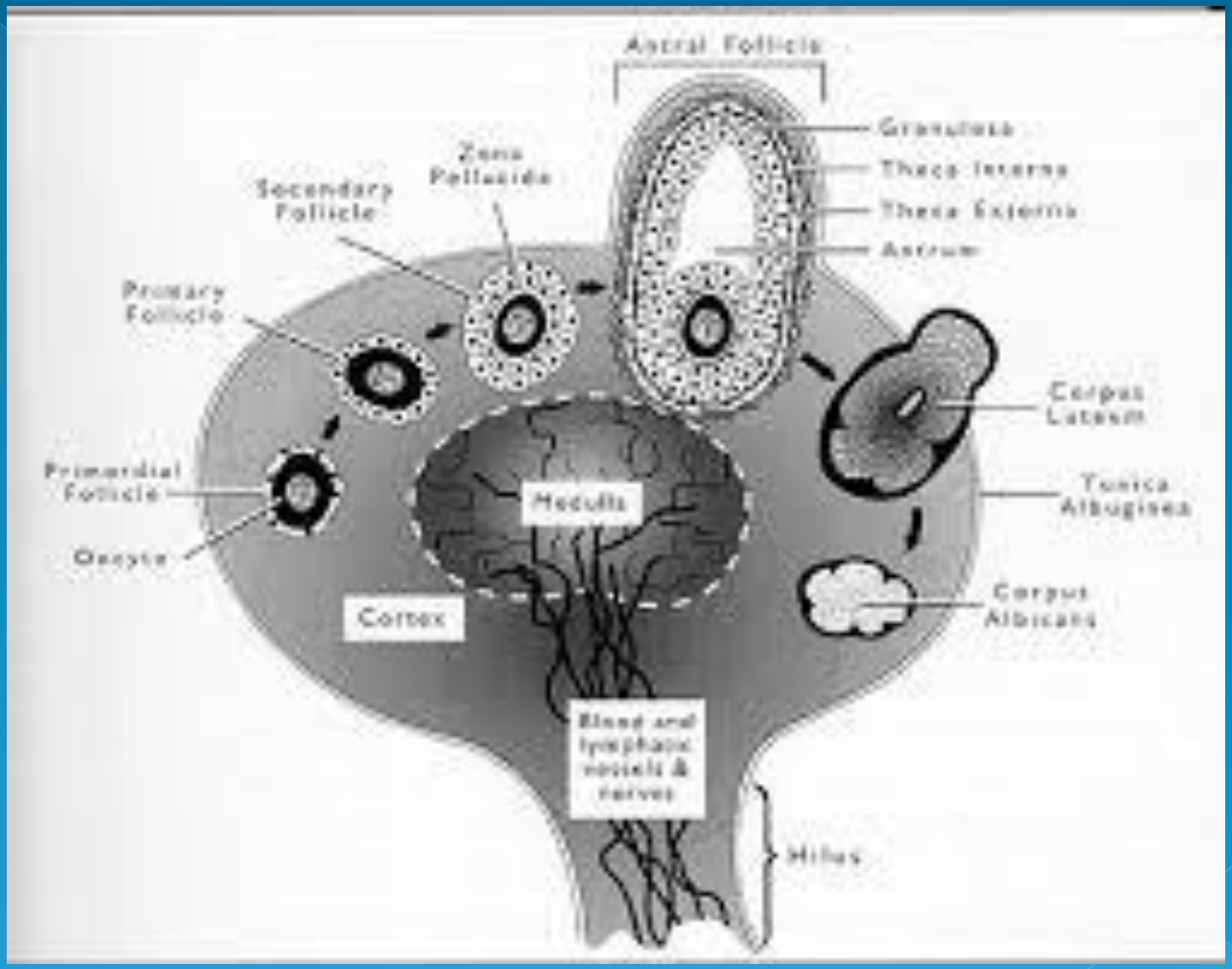
Antral Follicle
Granulosa
Theca Interna
Theca Externa
Antrum
Zona Pellucida
Secondary Follicle
Primary Follicle
Corpus Luteum
Primordial Follicle
Oocyte
Medulla
Tunica Albuginea
Cortex
Corpus Albicans
Blood and lymphatic vessels & nerves
Hilus

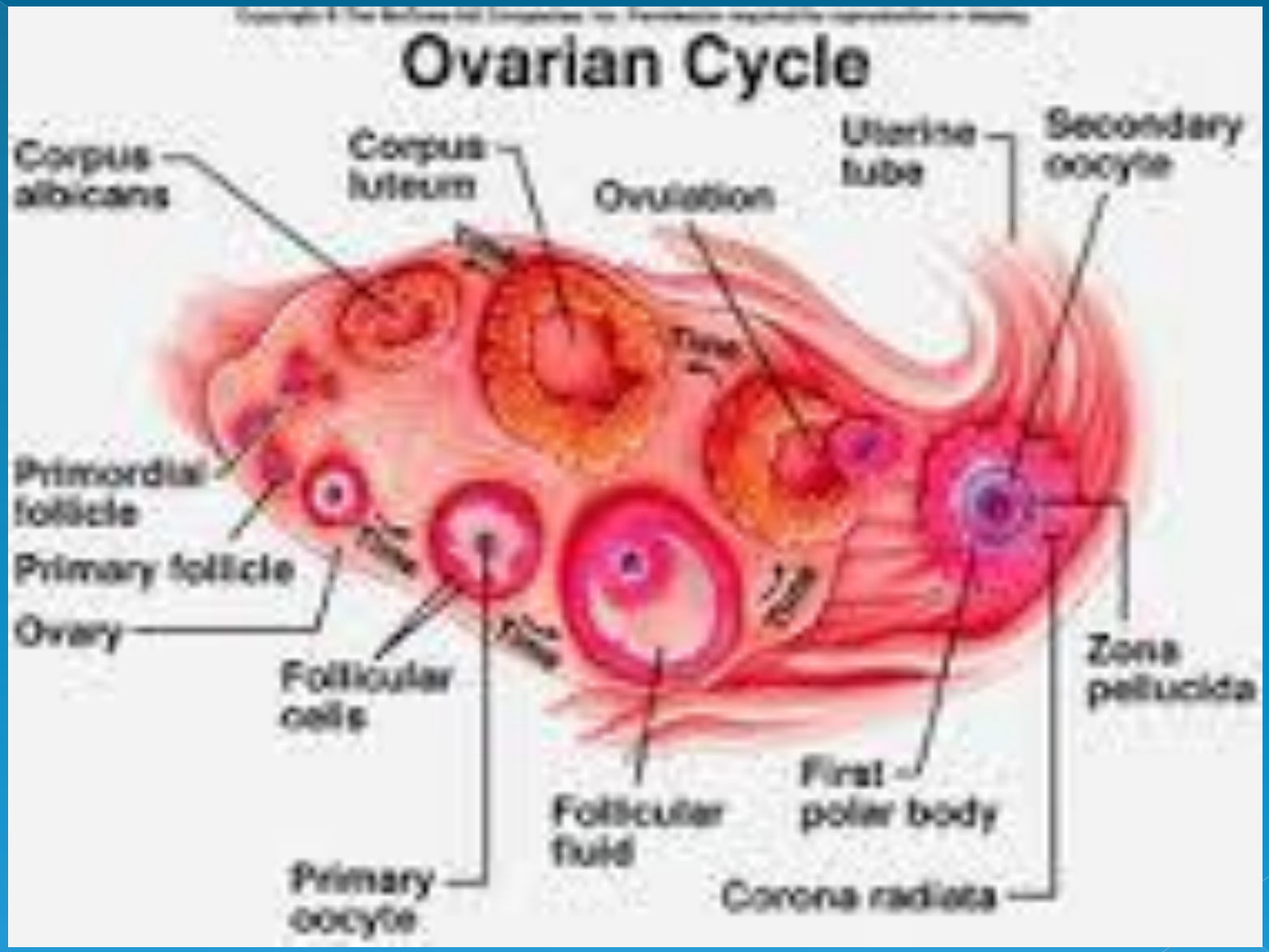
Ovarian Cycle
Corpus albicans
Corpus luteum
Ovulation
Uterine tube
Secondary oocyte
Primordial follicle
Primary follicle
Ovary
Follicular cells
Primary oocyte
Follicular fluid
First polar body
Corona radiata
Zona pellucida

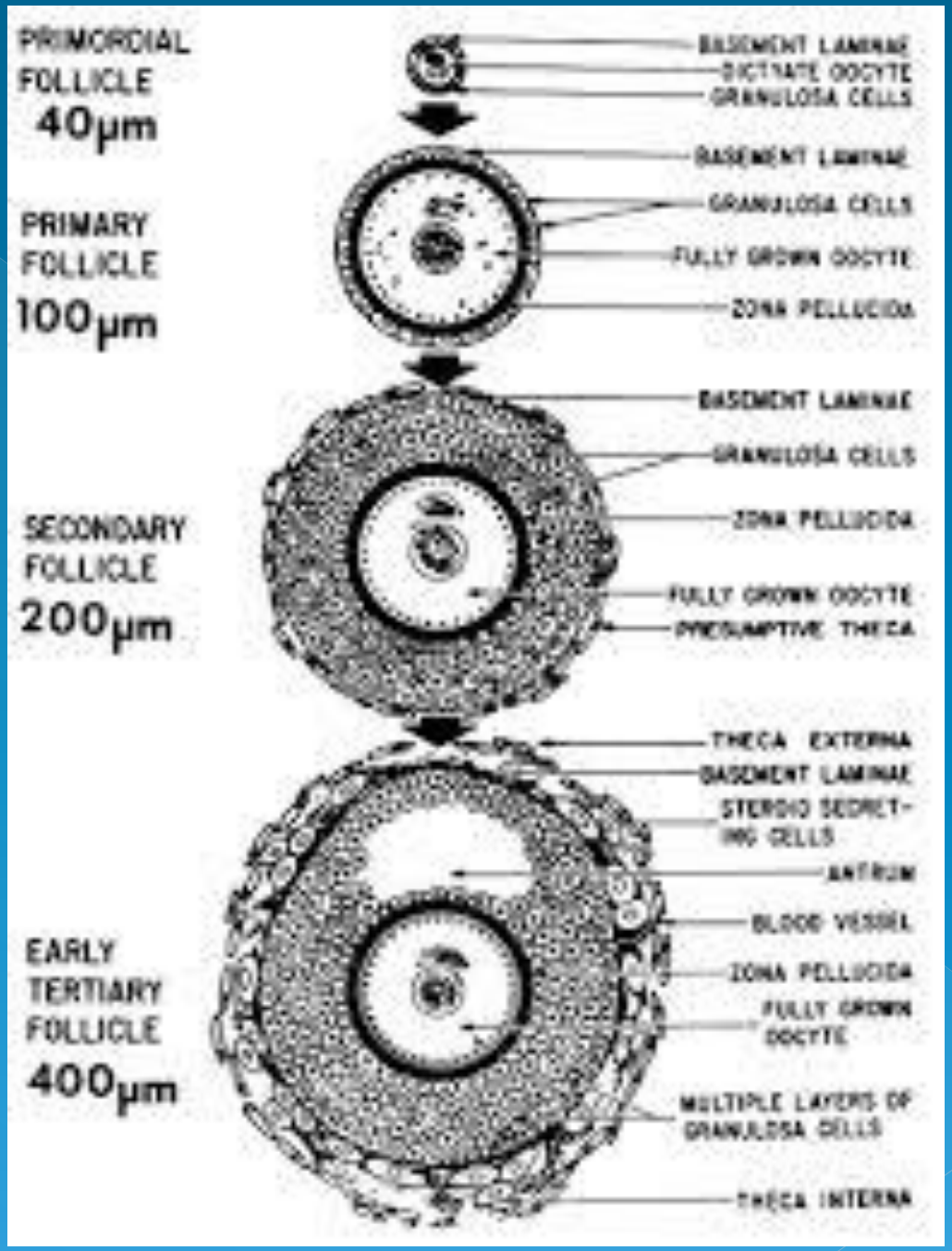
PRIMORDIAL FOLLICLE 40μm
BASEMENT LAMINAE
DICTYATE OOCYTE
GRANULOSA CELLS
PRIMARY FOLLICLE 100μm
BASEMENT LAMINAE
GRANULOSA CELLS
FULLY GROWN OOCYTE
ZONA PELLUCIDA
SECONDARY FOLLICLE 200μm
BASEMENT LAMINAE
GRANULOSA CELLS
ZONA PELLUCIDA
FULLY GROWN OOCYTE
PRESUMPTIVE THECA
EARLY TERTIARY FOLLICLE 400μm
THECA EXTERNA
BASEMENT LAMINAE
STEROID SECRETING CELLS
ANTRUM
BLOOD VESSEL
ZONA PELLUCIDA
FULLY GROWN OOCYTE
MULTIPLE LAYERS OF GRANULOSA CELLS
THECA INTERNA

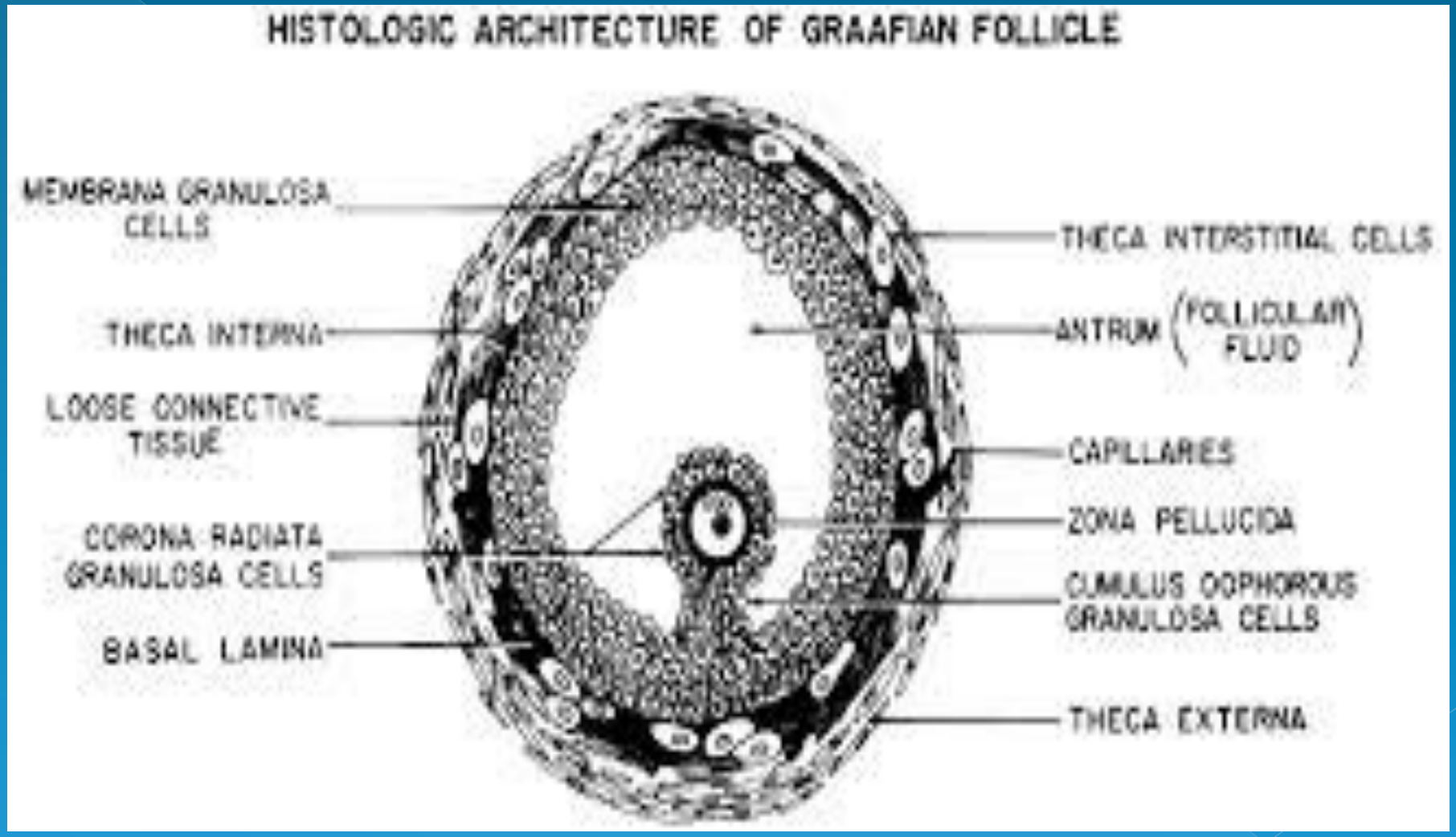
HISTOLOGIC ARCHITECTURE OF GRAAFIAN FOLLICLE
MEMBRANA GRANULOSA CELLS
THECA INTERNA
LOOSE CONNECTIVE TISSUE
CORONA RADIATA GRANULOSA CELLS
BASAL LAMINA
THECA INTERSTITIAL CELLS
ANTRUM (FOLLICULAR FLUID)
CAPILLARIES
ZONA PELLUCIDA
CUMULUS OOPHOROUS GRANULOSA CELLS
THECA EXTERNA

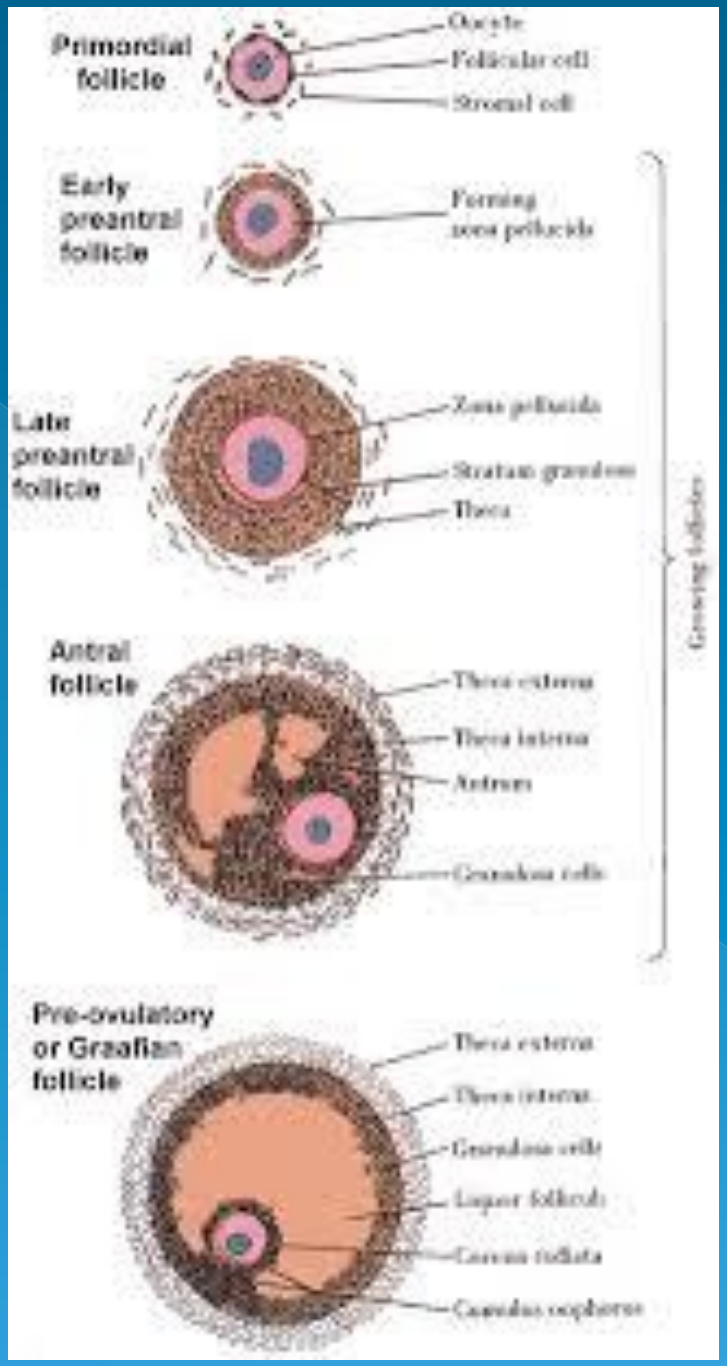
Primordial follicle
Oocyte
Follicular cell
Stromal cell
Early preantral follicle
Forming zona pellucida
Late preantral follicle
Zona pellucida
Stratum granulosa
Theca
Growing follicles
Antral follicle
Theca externa
Theca interna
Antrum
Granulosa cells
Pre-ovulatory or Graafian follicle
Theca externa
Theca interna
Granulosa cells
Liquor folliculi
Corona radiata
Cumulus oophorus

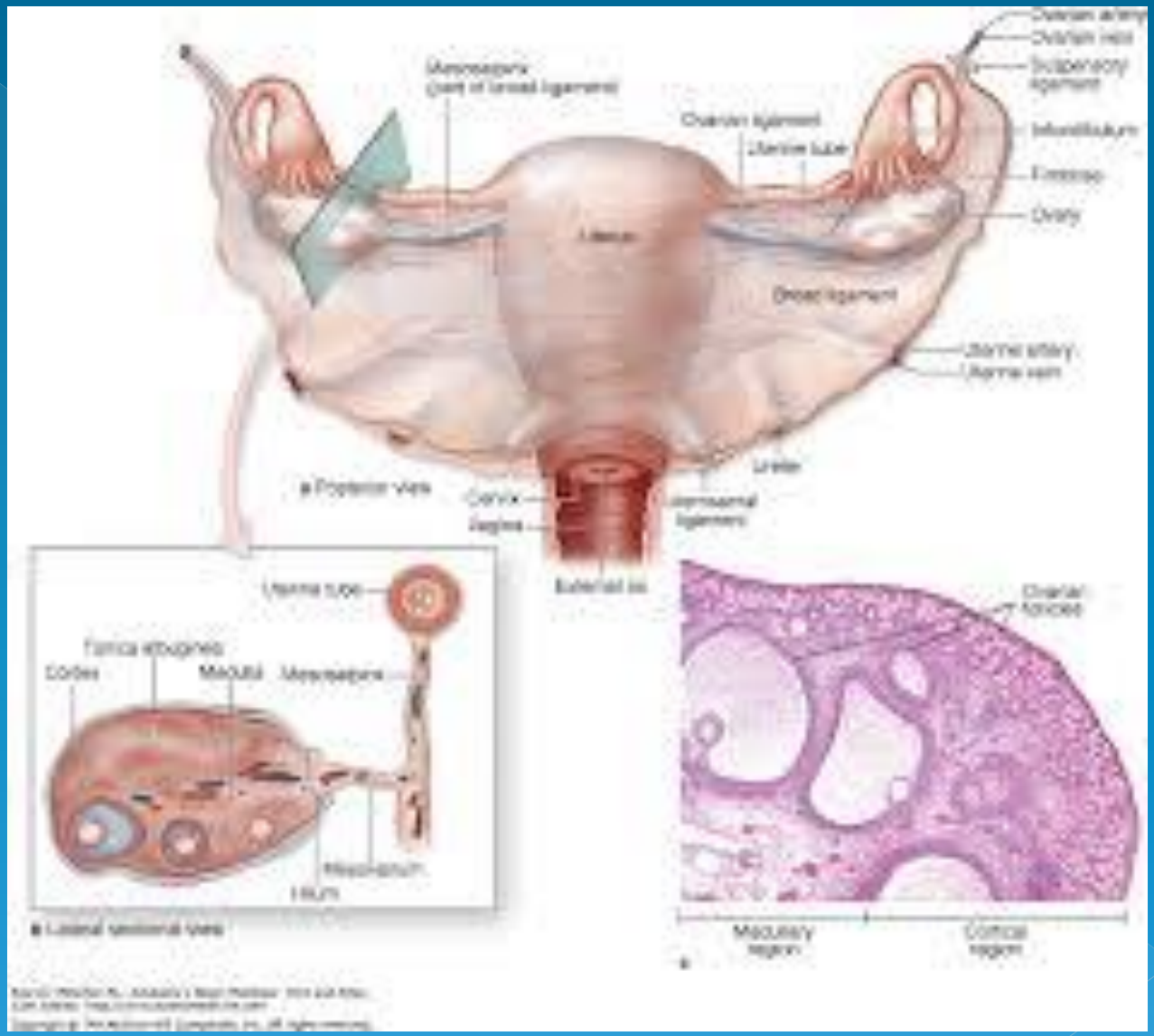
Ovarian artery
Ovarian vein
Suspensory ligament
Infundibulum
Fimbriae
Ovary
Uterosacral ligament
(part of broad ligament)
Ovarian ligament
Uterine tube
Broad ligament
Uterine artery
Uterine vein
Ureter
Posterior view
Cervix
Vagina
Uterosacral ligaments
External os
Uterine tube
Tunica albuginea
Cortex
Medulla
Mesosalpinx
Mesovarium
Hilum
Lateral sectional view
Ovarian follicles
Medullary region
Cortical region

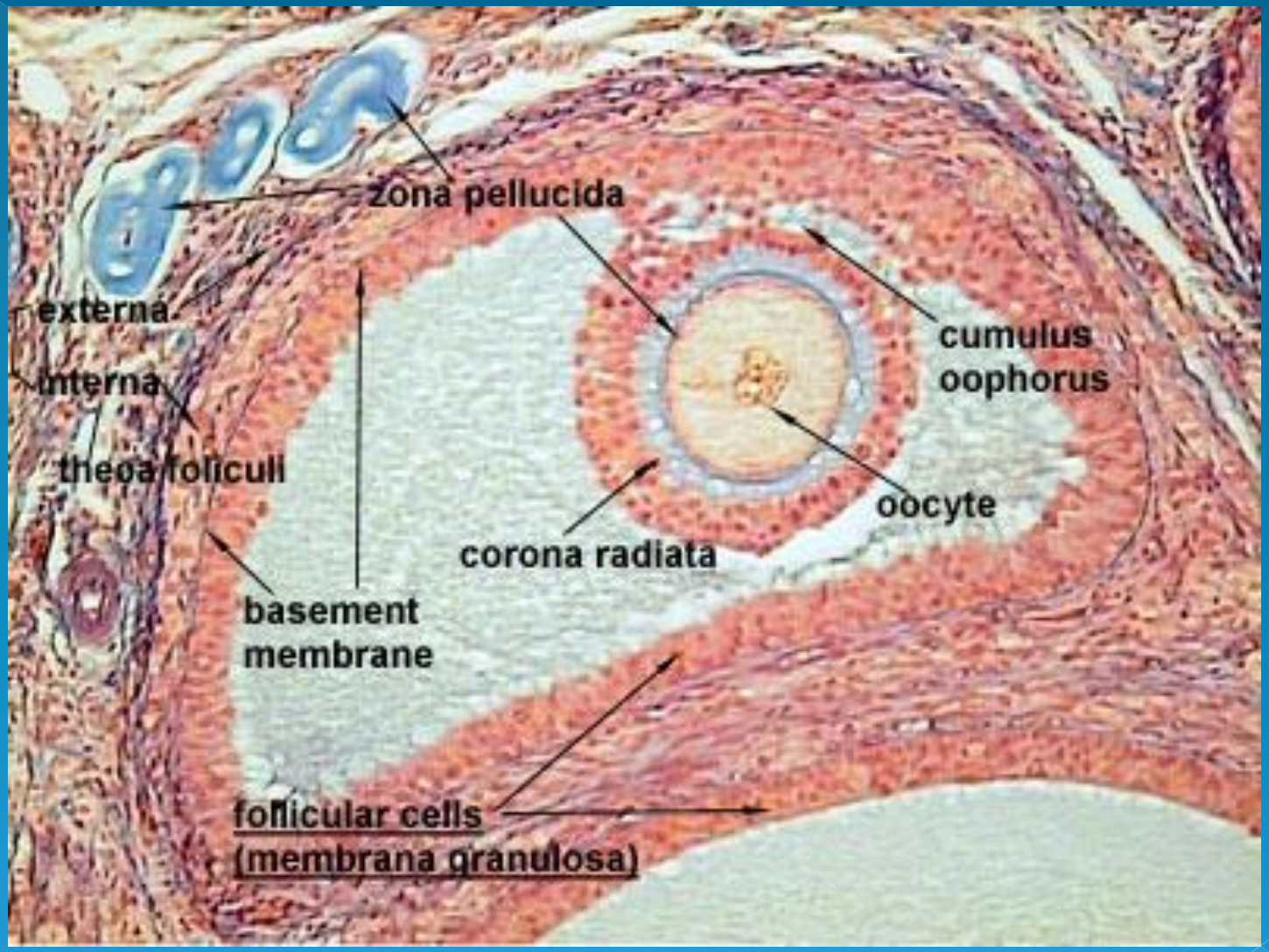
zona pellucida
externa
interna
theca foliculi
basement
membrane
cumulus
oophorus
oocyte
corona radiata
follicular cells
(membrana granulosa)

Ovulation

- It is the rupture of mature follicle and the release of the secondary oocyte.

- Before ovulation, the cumulus oophorus looses its connection with the stratum granulosum and the secondary oocyte with the corona radiata become free in the follicular fluid.

- An increase in the amount of liquor folliculi causes the follicle to swell.

- The follicular wall becomes thin and transparent at the future site of follicular rupture, the stigma.

- Changes in the wall of the follicle preceding rupture are caused by the release of lutinizing hormone (**LH**) from the pituitary .

- These processes cause rupture to the follicle at the weakest site, the **stigma** and the release of the secondary oocyte with the corona radiata (except in ruminant) and liquor folliculi from the ovary and the oocyte enters the **infundibulum** of the uterine tube.

- If the oocyte is not fertilized within 24 hours, it degenerates.

- Most domestic animals ovulate spontaneously, but ovulation in queen is induced by a copulatory stimulus.

➢ **Corpus luteum**

- The corpus luteum is a temporary endocrine gland formed by the remnant of the follicle after ovulation.

- After rupture of the follicle, the follicular wall collapses and the granulosa cells are thrown into folds.

- The rupture results in some bleeding.

- The blood clot and mix with the remaining liquor folliculi and occupy the central part of the developing corpus luteum which is now called corpus hemorrhagicum.

- The granulosa cells enlarge (hypertrophy) and increase in number by mitotic division (hyperplasia) and are thus termed the granulosa lutein cells or large luteal cells.

- A yellow pigment, lutein, appears in the luteal cells in cow, mare and carnivores and absent in ewe, goat and sow.

- The cells of the theca interna undergo hypertrophy and hyperplasia forming the theca lutein cells or small luteal cells.

- These cells aggregate peripherally, stain more intense and have smaller darker nuclei than those of the larger granulosa lutein cells.

- The two luteal cells produce **progesterone**.

- Blood capillaries of the theca interna grow in among the cords and clumps of lutein cells forming a typical endocrine gland, <u>the corpus luteum.</u>

- The **theca externa** remains <u>unchanged</u> as a fibrous capsule surrounding the corpus luteum.

- **If fertilization dose not occur**, the formed corpus luteum is known as <u>corpus luteum periodicum</u> or <u>cyclic corpus luteum</u> which undergoes rapid degeneration.

- If fertilization occur, the formed corpus luteum persists until the end of pregnancy.

- It is known as corpus luteum of pregnancy or corpus lutem gravidatis.

- It prevents the animal from coming in heat and prevents ovulation.

- The connective tissue scar which remains after the degeneration of the corpus luteum is called the corpus albicans.

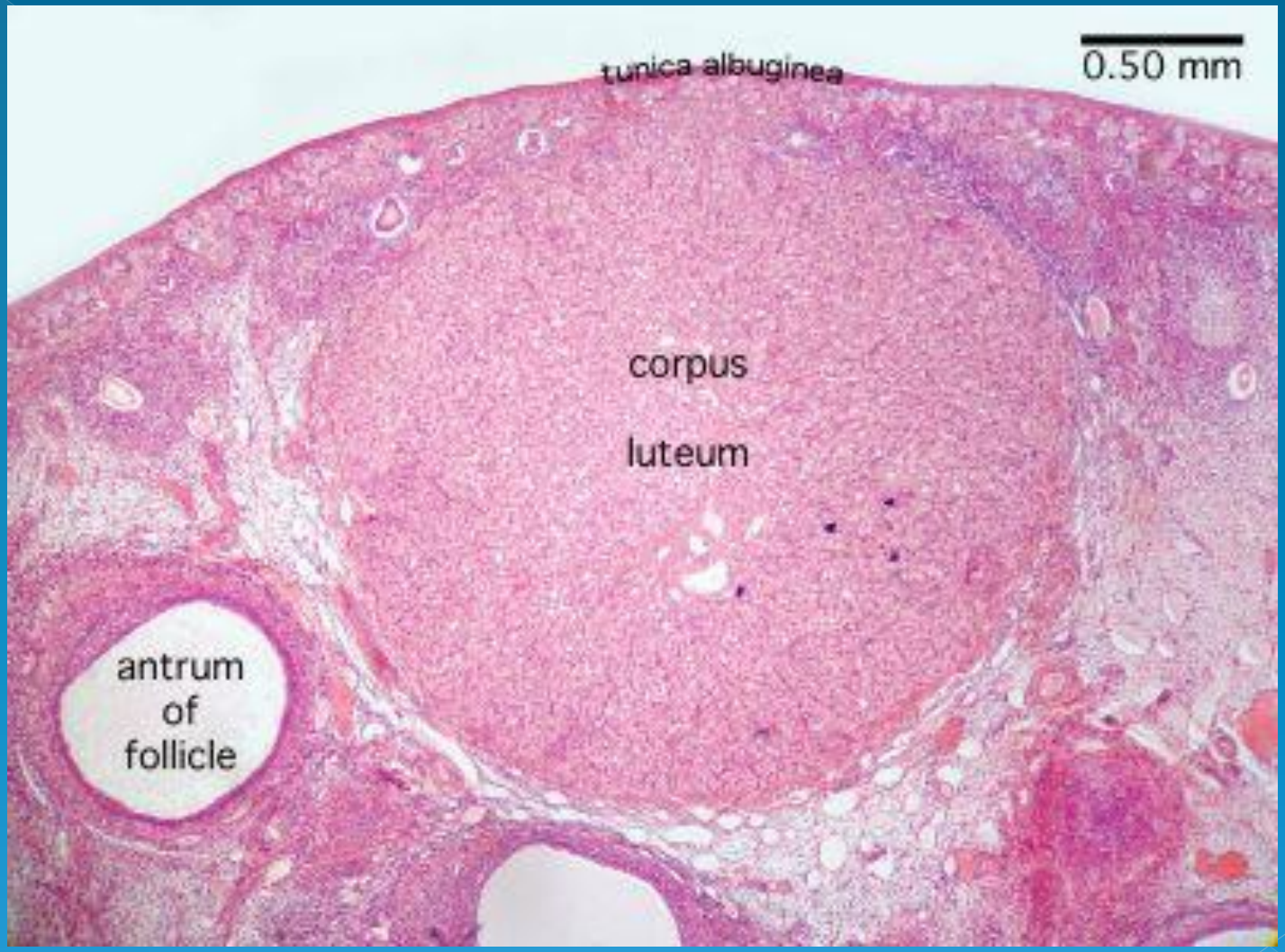
tunica albuginea
0.50 mm
corpus
luteum
antrum
of
follicle

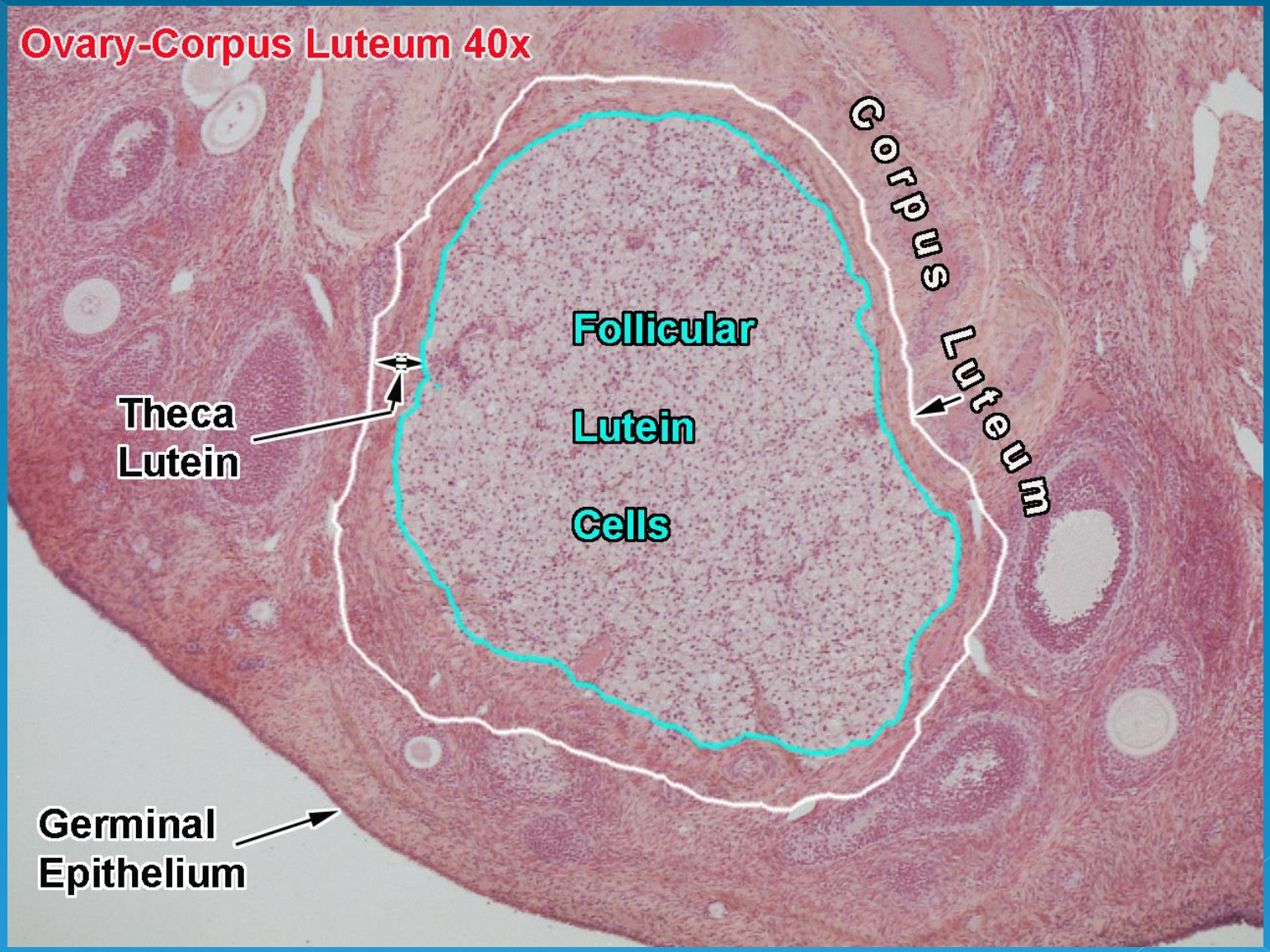
Ovary-Corpus Luteum 40x
Corpus Luteum
Follicular
Lutein
Cells
Theca
Lutein
Germinal
Epithelium

➢ Atresia and Interstitial endocrine cells

- Atresia is the degeneration of many ovarian follicles at various stages of development.

- In each cycle, one or few ovarian follicles reach maturity and ovulate from the ovary.

- The remaining follicles undergo atresia.

- During atresis the granulosa cells show nuclear pyknosis and chromatolysis.

- The basal lamina may fold, thicken and hyalinize, it is then called the glassy membrane.

- Eventually, atretic follicles are resorbed, except that small fibrous tissue scar may remain after atresia of mature follicles.

- In cow, the atresia of primary and secondary follicles shows degeneration of the oocyte before the follicular cells, whereas in tertiary follicles, the reverse is true.

- In bovine, the atretic changes of tertiary follicles may result in the formation of two different types of atretic follicles:

1- obliterative and 2- cystic.

- In oblitrative atresia, the granulosa and theca layers both infold, hypertrophy and extended inward to occupy the antrum.

- In cystic atresia both the granulosa and theca layers may atrophy or only the granulosa layer may atrophy and the theca layer may lutenized, fibrotic or hyalinize around the antrum.

- In cystic atresia the theca interna cells may continue to produce androgens after the regression of the granulosa cells which converted the androgen to estrogen

- **In bitch, queen and rodents**, interstitial endocrine cells are prominent.

- They arise from the theca interna cells of atretic tertiary (antral) follicles or from hypertrophied granulosa cells of atretic preantral (secondary) follicles.

- They are usually absent from the ovaries of other adult domestic animals.

❖ Medulla

- It is the inner area of the ovary containing nerves, many large and coiled blood vessels and lymph vessels.

- It consists of loose connective tissue and strands of smooth muscle continuous with those of the mesovarium.

- **Retia ovarii** are present in the medulla, they are networks of irregular channels lined by a cuboidal epithelium or solid cellular cords.

- They are prominent in **carnivores** and **ruminant**.

Hormones of the Ovary

- At puberty, the pituitary FSH stimulates the growth of the ovarian follicles during the first half of the ovarian cycle.

- The growing follicles produce estrogen, whose high midcycle level cause negative feed back on FSH production.

- This stimulate the LH surge from the pituitary which stimulates ovulation and formation and maintenance of the corpus luteum.

- The corpus luteum produces progesterone which inhibits LH production causing the corpus luteum to degenerate unless fertilization occurs.

- If fertilization occurs and implants in the uterus, chorionic gonadotropin produced by the developing placenta maintains the corpus luteum in the absence of LH.

❑ Uterine tubes (oviducts, Fallopian tubes)

-The uterine tubes are paired tortuous muscular tubes that extend from the region of the ovary to the uterine horns and convey ova, spermatozoa and zygotes.

- It is divided into three segments:

1- Infundibulum

- it is a large funnel-shaped portion, open near the ovary.

- It has finger-like extensions of its mucosal folds, the fimbriae in mare.

2- Ampulla

- it is a thin-walled, wide middle segment, contains .
- extensive branched mucosal folds.
- The caudal ampulla is the site of fertilization.

3- Isthmus

- it is a narrow segment joining the uterus.
- The epithelium is simple columnar or pseudostratified columnar with motile cilia in most cells.
- Both ciliated and non ciliated cells possess microvilli.
- The non ciliated cells have a secretory activity.

Oviduct H&E
serosa
muscularis
mucosa

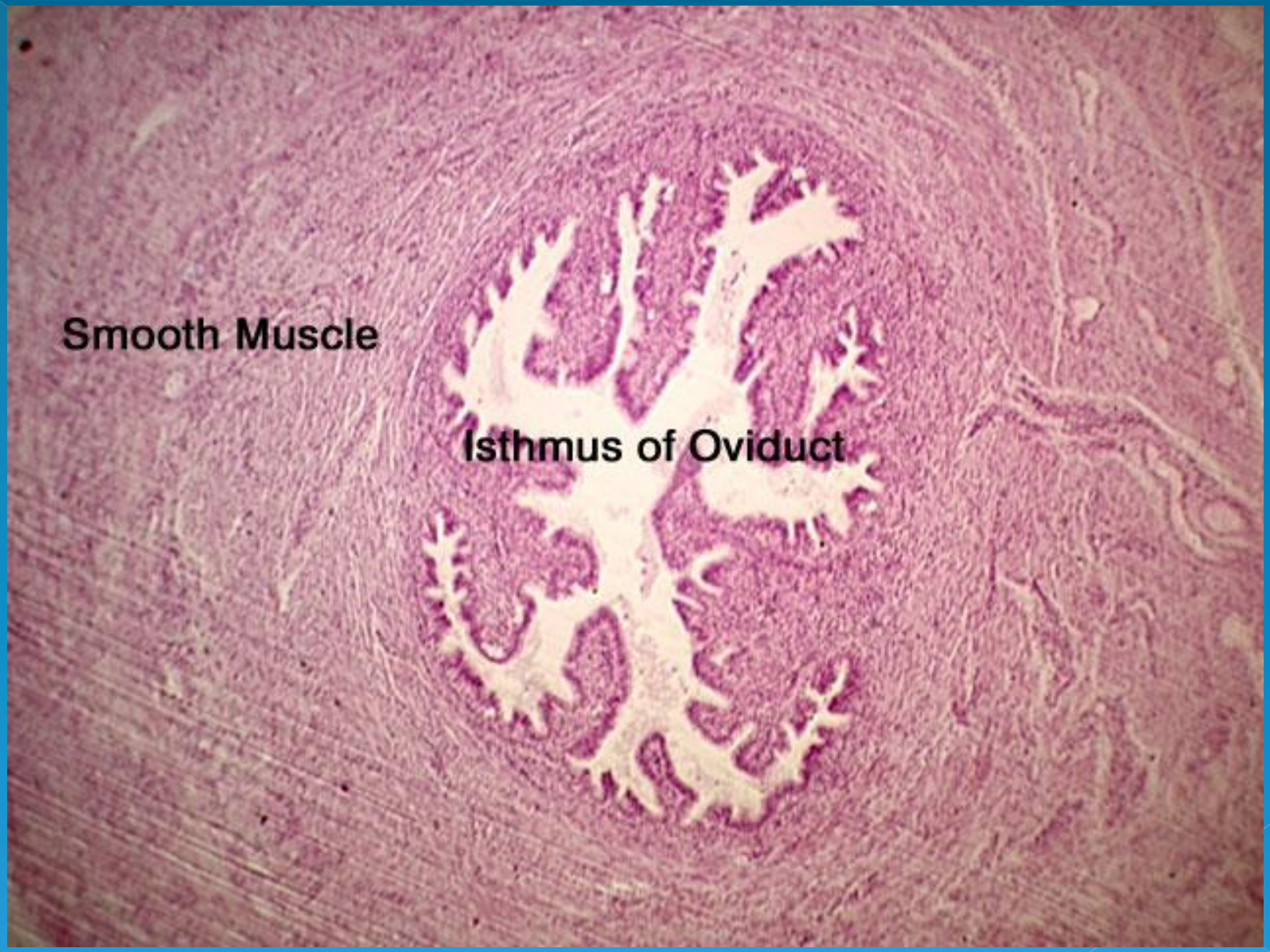
Smooth Muscle
Isthmus of Oviduct

❖ Uterus

-It is a muscular organ found in the pelvic cavity.

- It is the site of **implantation** and development of the embryo.

- In domestic mammals the uterus is **bicornuate type.**

- It consists of **two horns** connected to the uterine tubes, body (corpus) and a neck (cervix) which joins the vagina.

- In primates, the entire uterus is a single tube called the uterus simplex.

- The uterine wall consists of three layers:

1- the muscosa-submucosa or endometrium.

2- The tunica muscularis or myometrium.

3- The serosa or perimetrium.

Endometrium

- The endometrium is composed of two zones: the superficial layer called the functional zone, degenerates partially or fully after estrus or after pregnancy.

- A thin deep layer, the basal zone, persists after these events and the functional zone is restored from this layer.

- The surface epithelium of the functional zone is simple columnar in mare, bitch and queen. It is pseudostratified columnar or simple columnar in sow and ruminant.

- The subepithelial, superficial part of the functional zone consists of a richly vascularized loose connective tissue with many fibrocytes, macrophages and mast cells.

- Neutrophils, eosinophils, lymphocytes and plasma cells are also present.

- - The deep part of the functional zone consists of loose connective tissue that is less cellular than that of the superficial part.

- In ruminant, during estrus, large irregular fluid-filled spaces are present in the functional zone, this is termed endometrial edema.

- Simple coiled, branched tubular glands are present throughout the endometrium in most species.

- These glands are absent from the carancles of ruminant.

- The glands are lined by simple columnar secretory and nonsecretory ciliated cells.

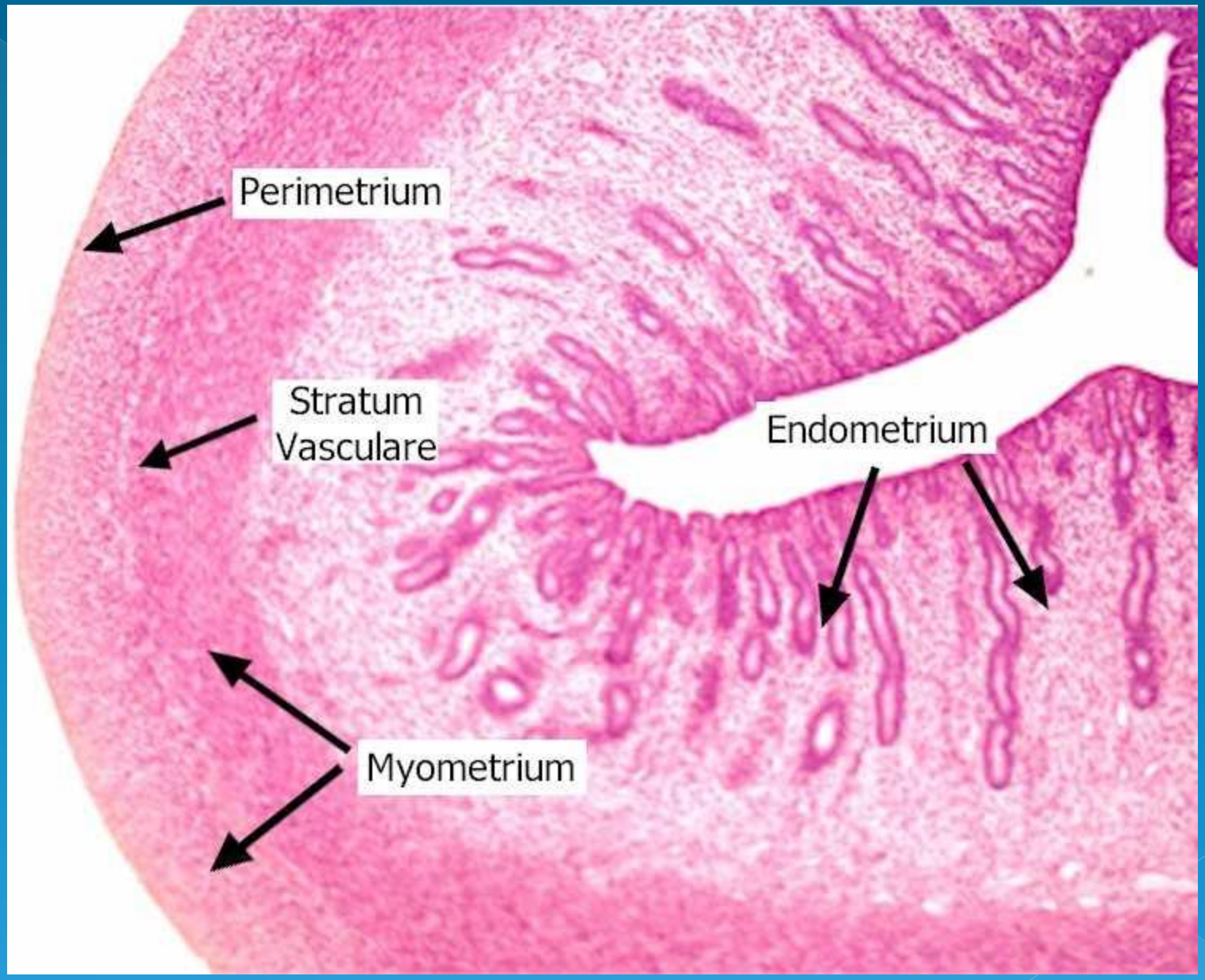
Perimetrium
Stratum
Vasculare
Endometrium
Myometrium

Uterus H&E proliferative phase
uterine glands
endometrium
myometrium

- Rising estrogen levels stimulate the growth and branching of the glands but coiling and copious secretion occur by progesterone stimulation.

- Endometrial cups occur in mare in early pregnancy after invasion by fetal cells.

- In ruminant, circumscribed thickening of the endometrium known as caruncles are present.

- They are rich in fibrocytes and have an extensive blood supply.

- In each uterine horn there are four rows, each row has 15 caruncles.

- They are dome-shaped in cow and cup-shaped in ewe.

- They are the sites of attachment of the maternal placenta to the fetal placenta.

Cyclic changes in the endometrium

Estrous cycle

1– Proestrus
2- Estrus
3 –Metestrus
4- Diestrus
5-Anestrus

- bitch and queen are monoestrus (having one or two estrous cycle per year followed by a long anestrus period).

- cow ,sow and rodents are polyestrus period (continuously cycling without anestrus period

- mare ,ewe and goat are seasonal polyestrus .

- During estrus , the secratory activity of the uterine glands is marked ,maximal congestion ,edema and hemorrhage (metrorrhaga).

- **Metorrhagia** : is a microscopic hemorrhages in the functional zone of the endometrium that begin before ovulation .

- At ovulation it becomes widespread in the center of the caruncles in cow .

- Capillaries rupture in the mucosa and blood accumulates in blisters

- It occurs in bovine and canine .

Myometrium

- It consists of a thick inner circular layer and and outer longitudinal layer of smooth muscle cells that increase in number and size during pregnancy.

- Between the two layers or deep in the inner layer is a vascular layer consisting of large arteries, veins and lymph vessels.

Perimetrium

- The perimetrium or the tunica serosa, consists of loose connective tissue covered by the peritoneal mesothelium.

- Smooth muscle cells occur in the perimetrium, also blood and lymph vessels and nerve fibers.

- The perimetrium, the longitudinal layer of the myometrium and the vascular layer of the myometrium are all continuous with corresponding structures in the broad ligament of the uterus.

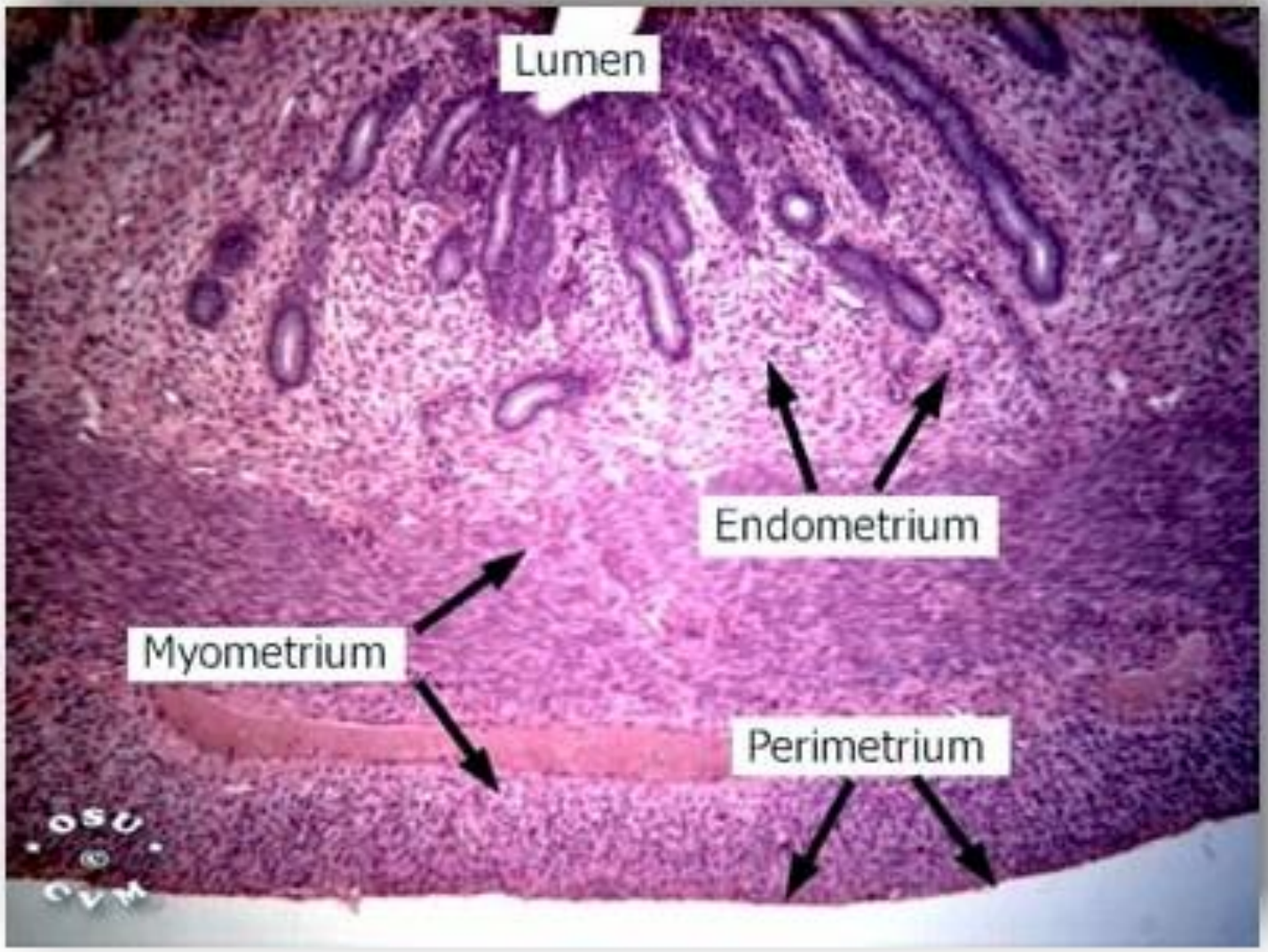
Lumen
Endometrium
Myometrium
Perimetrium
OSU
CVM

❖ Cervix

• The cervix or the neck of the uterus is thick-walled, muscular part rich in elastic fibers.

- The mucosa-submucosa forms high primary folds with secondary and tertiary folds.

- In cow four large circular folds and 15 to 25 longitudinal primary folds, each with secondary and tertiary folds.

- The uterine glands do not extend into the cervix.

- In most species, the epithelium is with many mucous secreting cells including goblet cells.

- Ciliated cells may present in some species.

- Simple tubular glands may be present in ruminant.
- In sow, the cervix may have a vaginal type of mucosa with startified squamous epithelium.

- The propria-submucosa consists of dense irregular connective tissue, which becomes edematous and loose during estrus.

- The tunica muscularis consists of inner circular and outer longitudinal smooth muscle layers.

- Elastic fibers are prominent in the circular layer.

- The tunica serosa consists of loose connective tissue.

❖ Vagina

- The vagina is a muscular tube extending from the cervix to the vestibule.

- Longitudinal mucosal-submucosal folds extend throughout the length of the vagina.

- In cow, circular folds are also present in the cranial portion of the vagina.

- Cyclic variations occur in epithelial height and structure.

- The vaginal mucosa is lined mostly by stratified squamous epithelium that increases in thickness during proestrus and estrus.

- In bovine, a surface layer of columnar and goblet cells is present on the stratified squamous epithelium in the cranial part of the vagina.

- In mare, the epithelial cells are polyhedral with layers of flattened cells on the surface.

- The propria-submucosa consists of loose or dense irregular connective tissue containing lymphatic nodules in the caudal part.

- The tunica muscularis consists of two or three layers.

- A thick inner circular layer of smooth muscle and a thin outer longitudinal layer.

- An additional thin longitudinal layer is present in sow, bitch and queen.

- The tunica adventitia or cranialy the serosa consists of loose connective tissue contains large vessels, nerves and ganglia.

- A thin longitudinal smooth muscle layer may be present in the tunica serosa and is referred as **muscularis serosa**.

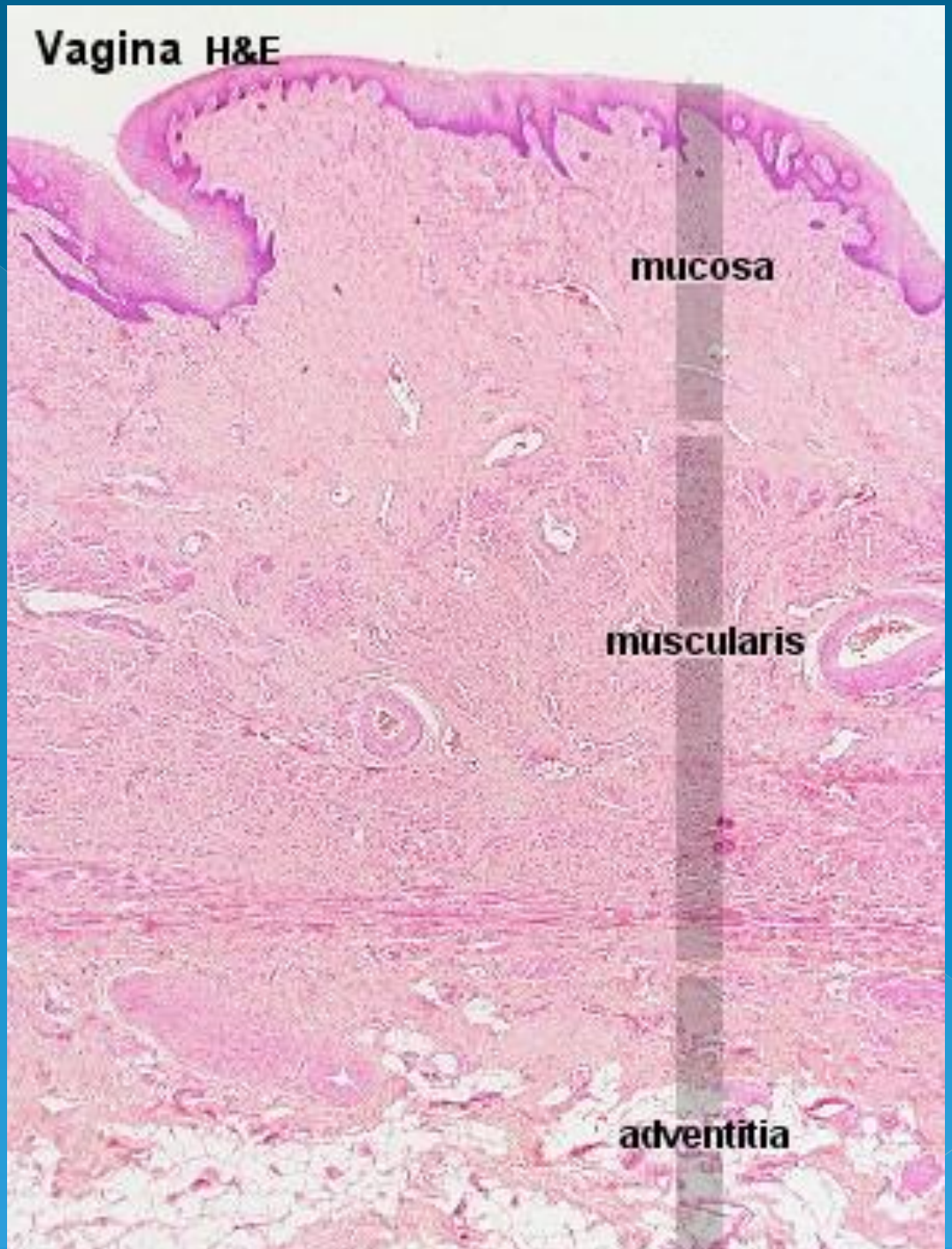
Vagina H&E
mucosa
muscularis
adventitia

❖ Vestibule, Clitoris and Vulva

- The wall of the vestibule is similar to that of the caudal portion of the vagina, except the presence of more lymphatic nodules, blood vessels, erectile cavernous tissue and venous plexus.

- They become congested during estrus.

- An erectile corpus cavernosum, called the bulbus vestibuli is present beneath the vestibular mucosa in mare and bitch.
- It resembles the corpus spongiosum penis.

- **Major vestibular glands**, are bilateral compound tubuloacinar mucous glands located in the deep part of the propria-submucosa.

- They occur in **ruminant** and **queen**.

- **Minor vestibular glands**, are bilateral small, branched tubular mucous glands scattered in the mucosa of **most domestic animals.**

❖ Clitoris

- The clitoris consists of paired, joined erectile corpora cavernosa clitoridis, a rudimentary glans clitoridis and a preputium clitoridis.

- In mare, the corpus cavernosum is well developed and the glans is functionally erectil only in mare.

- Nonerectile fibroelastic tissue replaces the glans in queen, sow and ewe.

❖ Vulva

- The vulva is formed by the labia vulvae, which are covered by skin that is richly supplied with apocrine and sebaceous glands.

-Striated muscle fibers of the constrictor vulvae are found in the hypodermis.

- The labia are well supplied with small blood and lymph vessels which become congested during estrus especially in sow and bitch.

Thank you